

^{1,2}A Li; ^{1,2}JW Pierrepont; ³L Walter; ⁴S McMahon, ⁵A Ellis, ¹Q Li

¹University of Sydney, NSW, Australia; ²Optimized Ortho, NSW, Australia; ³Peninsula Orthopaedics, NSW, Australia; ⁴Malabar Orthopaedics, VIC, Australia; ⁵OrthoNorth, NSW, Australia

Introduction

Routine post-operative X-rays are often used to determine cup orientation. However, measurements can be unreliable due to lack of control of pelvic position in relation to the X-ray plane. By contrast, CT scans offer increased accuracy with the drawback of additional cost to the healthcare system.

With the growing prevalence of pre-operative CT scans for more precise surgical planning, we investigated the accuracy of a 3D/2D registration technique for measuring post-operative cup orientation.

Methods

- 48 patients with pre- and post-operative CT scans, as well as a routine post-operative AP radiograph were identified from a previous study.
- The pre-operative 3D pelvis was matched to the post-operative AP X-ray (Mimics X-ray Module, Materialise, Belgium), Fig 1a.
- Next, the 3D cup geometry was matched to the post-operative AP X-ray (Mimics X-ray Module, Materialise, Belgium), Fig 1b.
- Knowing the 3D position of the cup relative to the pelvis allowed the cup orientation to be measured, Fig 1c.
- As a control, cup orientation was also measured directly from the post-operative CT.

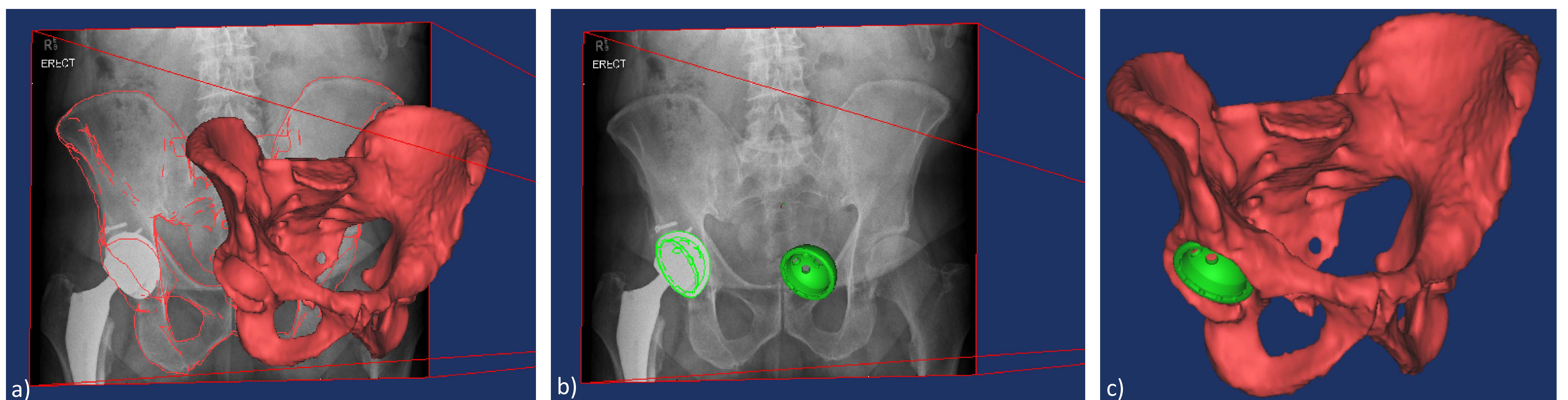


Fig 1. Registration of 3D pelvis model and cup to the 2D post-operative AP X-rays

Results

The Pearson correlation coefficients between 3D/2D registration and CT for cup inclination and anteversion were 0.98 and 0.97 respectively, Fig 2. The maximum inclination error was 3.5° and maximum anteversion error was 5.4°.

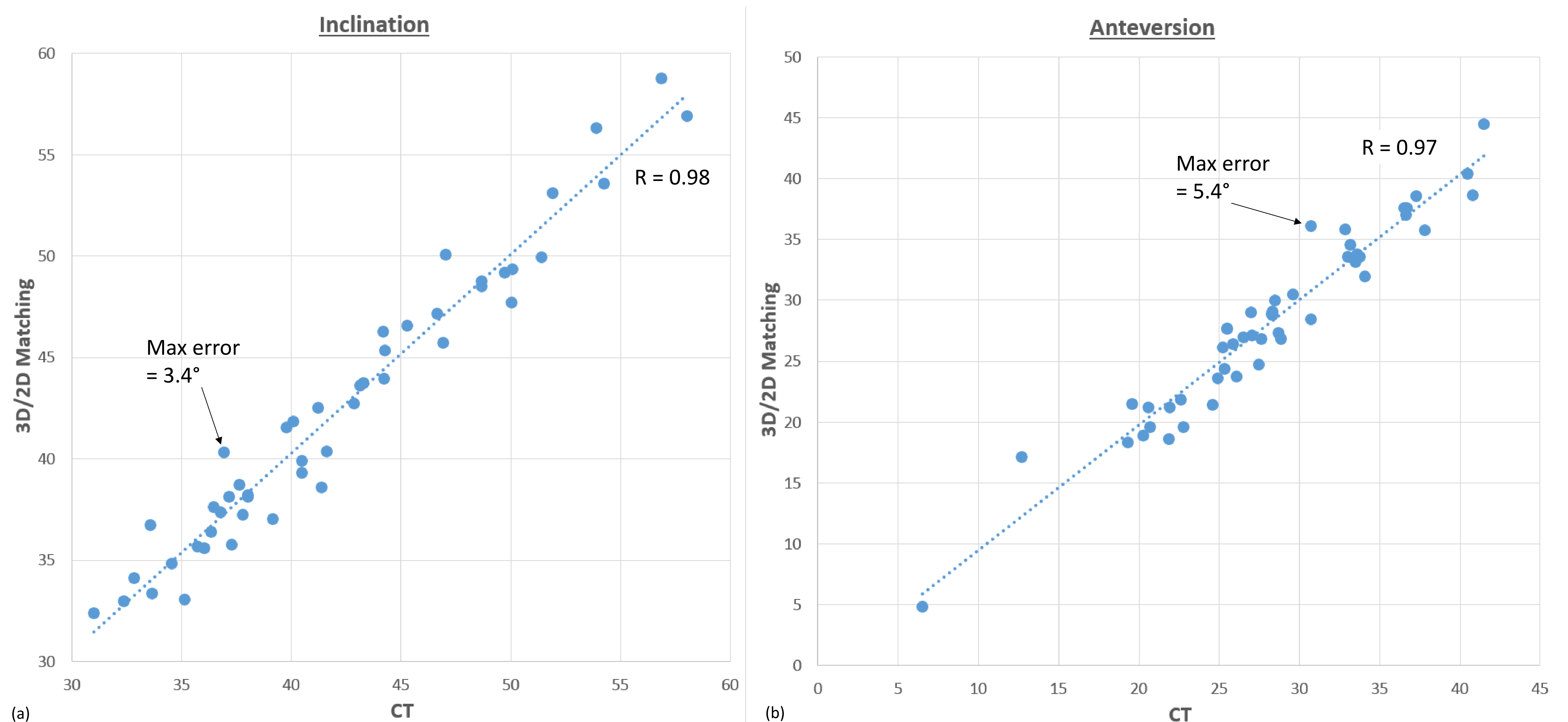


Fig 2. (a) Inclination values for 3D/2D matching versus CT generated orientation; (b) Anteversion values for 3D/2D matching versus CT generated orientation

Conclusion

3D/2D registration is a reliable and accurate method for determining acetabular cup orientation from a routine post-operative X-ray, providing a pre-operative CT is available.